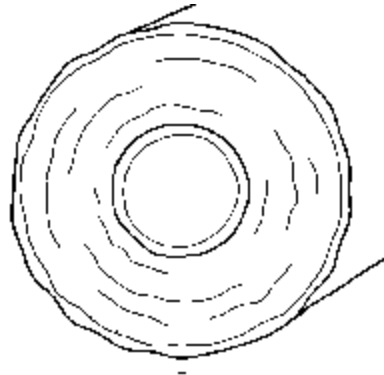
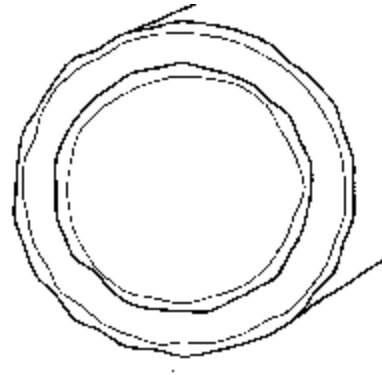


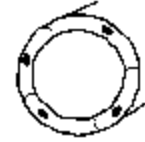Slide # 1



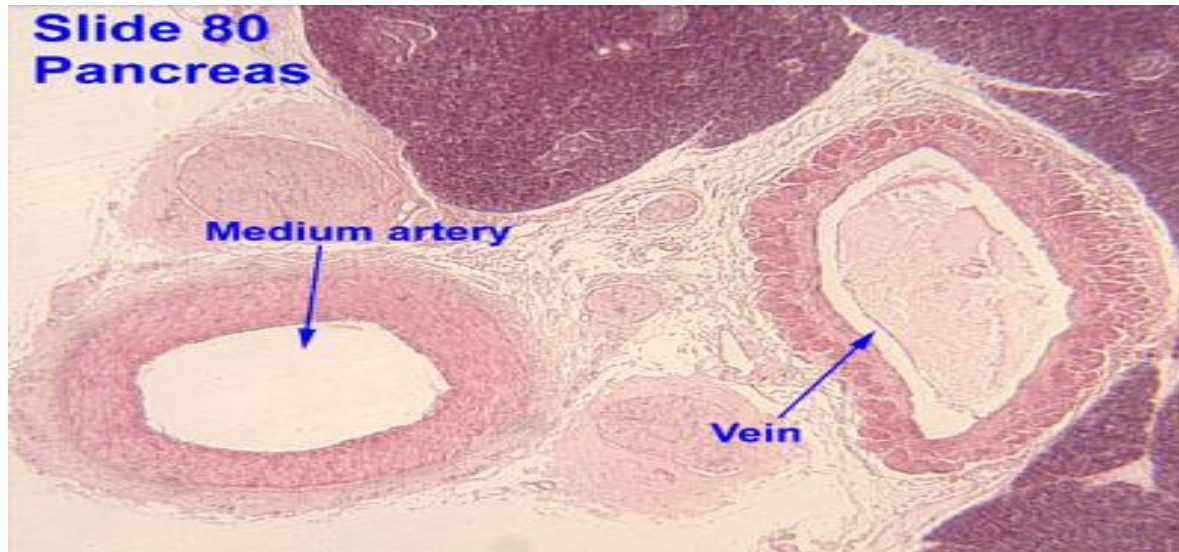
artery cross section



vein cross section

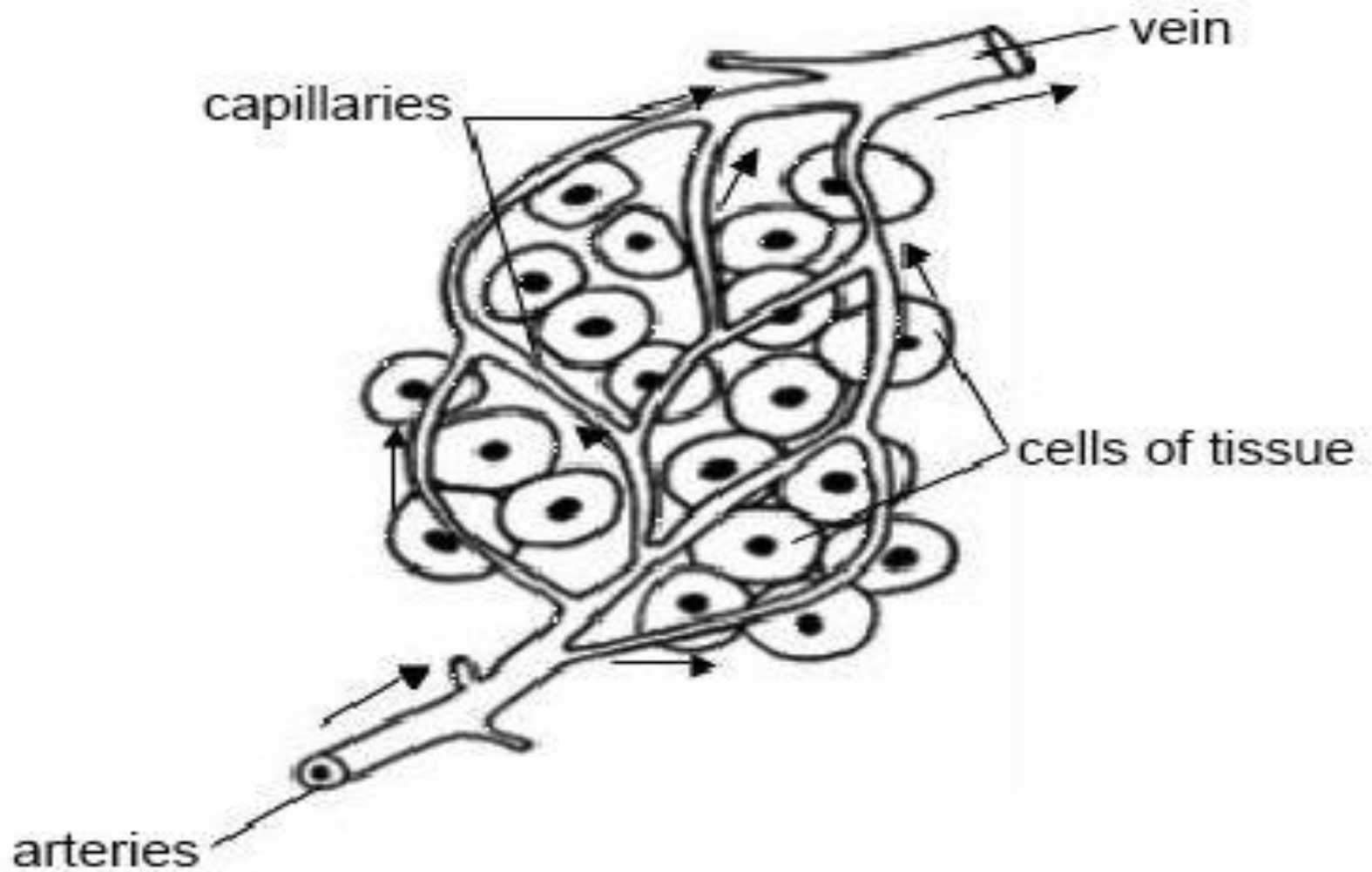


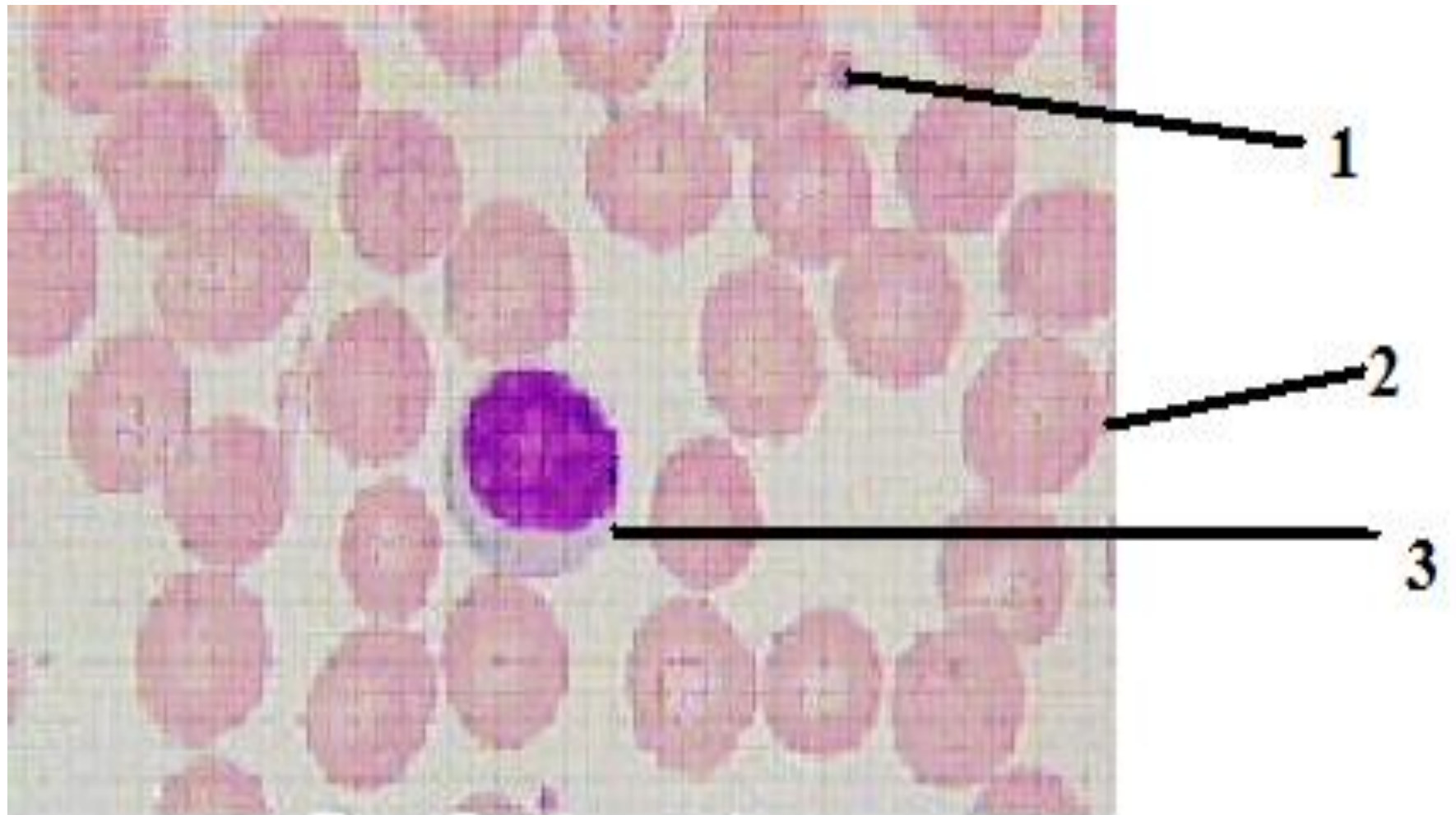
capillary cross section



http://www.ouhsc.edu/histology/Glass%20slides/80_09.jpg

Slide # 2





Normal Blood Smear Diagram

Blood Smear Disruption of Homeostasis Slide # 4

